HISTOLOGY NUTSHELL

Based on Notespaedia Elite series Anatomy Notes



Notespaedia.com

More than just notes...

Please Note:

- This is the *digital handwritten note* of **HISTOLOGY Snippets of Elite notes Based on Dr. Raviraj's Marrow 3.0 video and Dr. Pradeep Pawar's DAMS F2F 2019**
- **All the Slides/ Images/ Diagrams and Graphs discussed by the lecturer is added**
- **All the questions discussed by the lecturer is added**
- Additional Images from the web for better understanding is included
- Extra points from **Marrow Qbank/ Pearls** has been included
- Recent Year **AIIMS/ NEETPG** questions included
- **Red Box - MOST TESTED TOPIC** included
- **HIGHLIGHTING** is included which denote keywords of the **core concept** which is recommended to be used during your **revision**

ABBREVIATION

1. GT No. = DAMS Grand Test (No. order in DAMS test series)
2. CBT = DAMS COMPUTER BASED TEST
3. Q = Question from Marrow Qbank/ PrePG/ DAMS QB/ BHATIA QB/ PrepLadder QB
4. SWT = DAMS / MARROW subject wise test
5. CT = DAMS Classroom test

WARNING : THIS IS NOT THE COMPLETE VERSION OF ELITE NOTES

Please provide your valuable feedback and check our other notes in Telegram group - ***NOTESPAEDIA***

For any queries or corrections please contact us in WhatsApp @ 7356595629

Telegram = notespaedia
WhatsApp 7356595629

HISTOLOGY :-

Basic Tissue :

1) **Epithelial** → Most of organs
Function of epithelium → Fn. of organs.

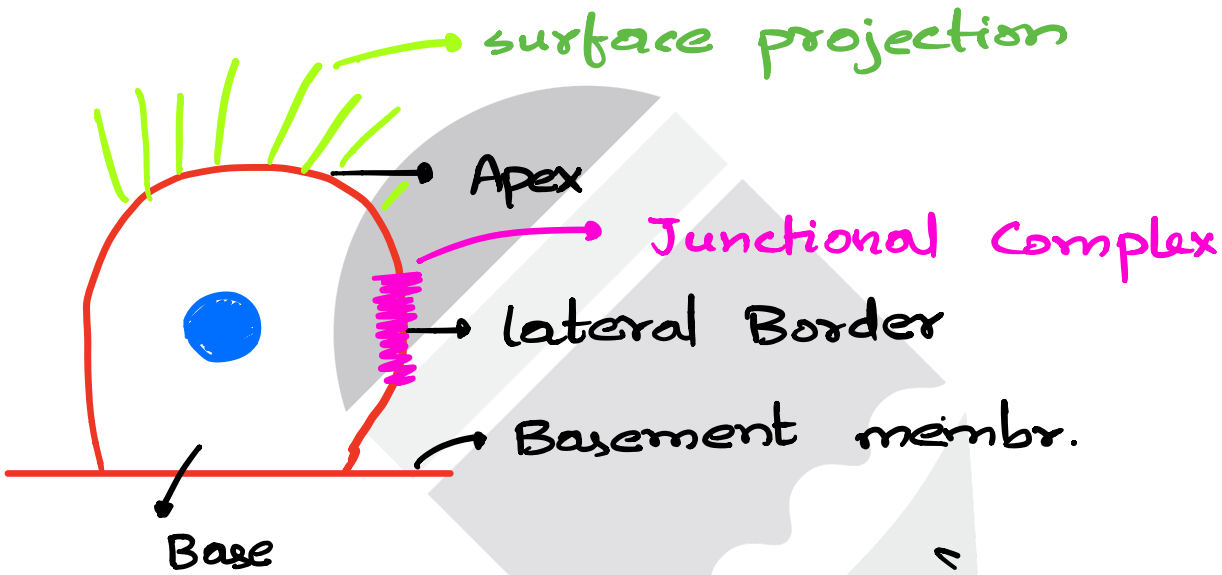

Classification of Epithelium

- Simple ⇓ Single Layer
  - simple squamous
  - cuboidal
  - columnar
- Stratified ⇓ Many Layers

Found in :-
1) Entire Body surface
2) Secretory structures
3) Neuro receptors.

Simple Squamous :-

1) H < W
2) Flat nucleus
3) Active transport / cell Exchange

⇒ Found in :-
i) All B.V (Endothelium)
ii) Body cavities {mesothelium}
iii) Bowman's Capsule
iv) Alveoli

Notespaedia
More than just notes...

Telegram = notespaedia
WhatsApp 7356595629

Simple Cuboidal

1) L = W

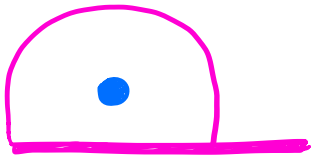

2) Nucleus Round

3) Found in areas
& secretion & absorptions. (INACTIVE)

Found in ⇒

1) Thyroid Follicles
2) Germinal Epithelium of ovary
3) Tubules

Simple Columnar Epithelium:-

1) Height > Width

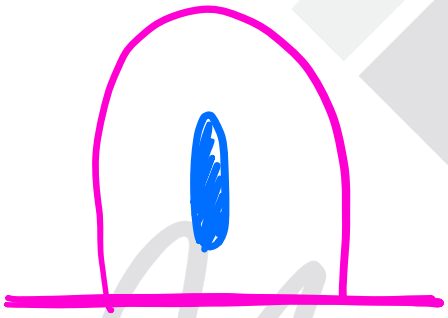

2) Elongated nucleus
3) Absorption & Secretion (ACTIVE)

Found in :-

1) Stomach
2) Small Intestine
3) Large Intestine
4) Simple columnar with Microvilli → gall bladder
5) Columnar & cilia.
   - Middle ear
   - Eustachian Tube
   - Ventricles of Brain

Notespaedia
More than just notes...

STRAIFIED

- St. Squamous
- St. Cuboidal
- St. Columnar.

⇒ Apical Cell layer (Top Layer) ⇒ Sq. → St. Sq

Telegram = notespaedia
WhatsApp 7356595629

Cub → St. Cub

Columnar → St. Columnar

① Stratified Squamous Epithelium

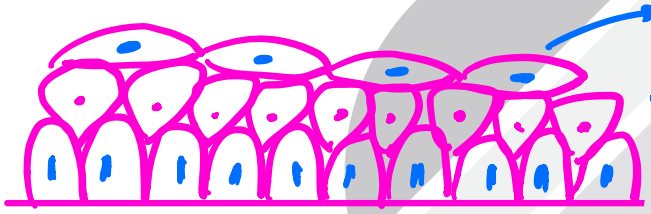

Apical layer ⇒ squamous.

Polygonal Layer

Basal Layer → mitotic

Found in :-

i) wear ever there is friction

- Epidermis skin
- Vagina
- 1st layer cornea
- Mucosa oral cavity
- Tongue
- Vocal Chord
- Tonsil
- Esophagus

Fnx : Barrier function.

② Stratified Cuboidal:

- Apical Layers will be cuboidal
- Ducts of all exocrine glands and sweat glands

Apical layer = cuboidal



Notespaedia
More than just notes...

WhatsApp 7356595629
Telegram = notespaedia

3) Str. Columnar.

- Apical layer → columnar
- Membranous urethra, Penile urethra

SPECIAL CATEGORY:

Q. 1) Psuedostratified :-

- Look like many layers [not so]
- Nucleus arranged in many layers. } Q. But cells are single layer
- All the cells attatched to basement membrane.
- Surface projection → CILIA ~ psuedostratified ciliated
  - ↳ Respiratory epithelium

Eg:- .Trachea
- .1° bronchus
- .2° bronchus
- Larynx

2) Transitional Epithelium:-

- Found in urinary system K/a → UROTHELIUM

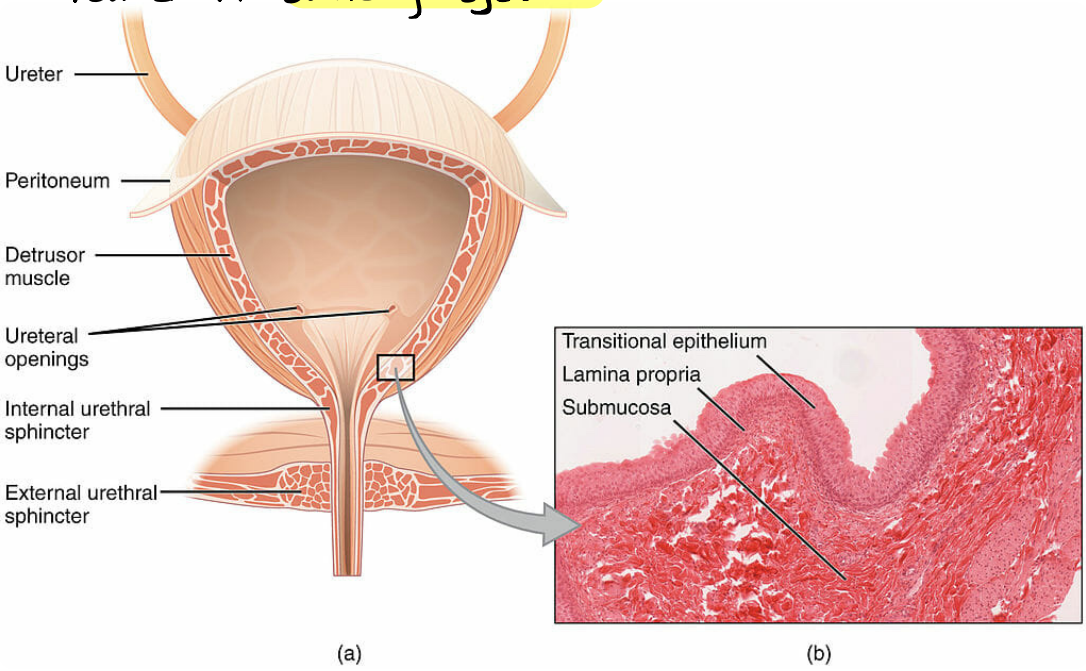

Telegram = notespaedia
WhatsApp 7356595629

- BLADDER

Relaxed

BLADDER

DISTENDED

Figure 3.7b Histology of Pseudostratified Ciliated Columnar and Transitional Epithelia

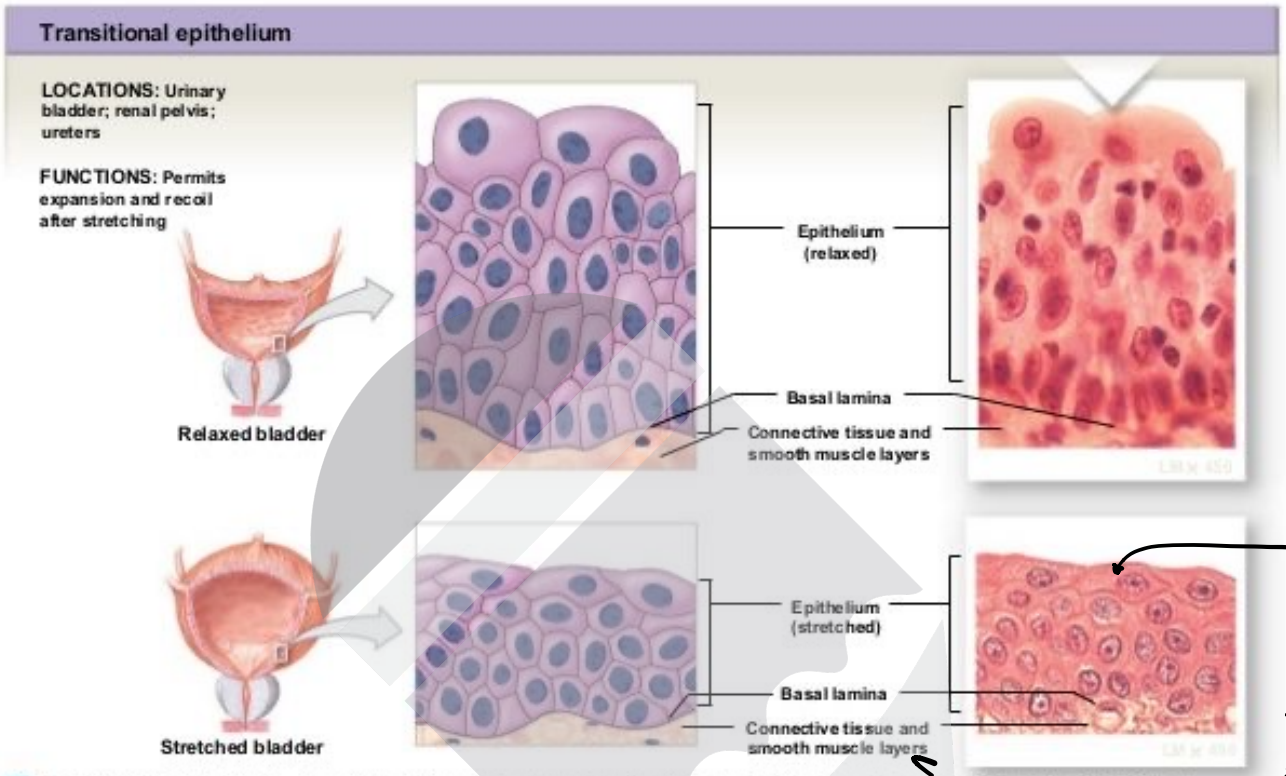

glucocalysin
⇓
blocks toxic substances

b Transitional epithelium. A sectional view of the transitional epithelium lining the urinary bladder. The cells from an empty bladder are in the relaxed state, while those lining a full urinary bladder show the effects of stretching on the arrangement of cells in the epithelium.

© 2012 Pearson Education, Inc.

SURFACE PROJECTIONS

Surface Projections

1) Micro villi = Brush border
↳ ↑se Surface Area
- Found in Gall bladder
  fnx: stores and conc. of Bile. (LIVER)

2) Sterocilia: Villi longer in length.
- Found in Reproductive organs
  Hair cells.

3) Cilia → Hair like projections
↳ Move/propel particle.

Notespaedia
More than just notes...

Telegram = notespaedia
WhatsApp 7356595629

Ciliated simple columnar epithelium ⇐
- Found in
  - * fallopian tube
  - * Uterus
  - * Ventricle
  - * Middle Ear.

JUNCTIONAL COMPLEX

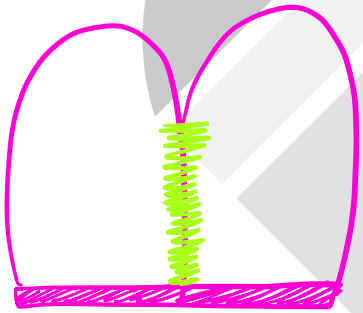

→ Lateral Border {provided with junctional complex}

TIGHT Jn	ANCHORING JN.	Gap Junction
a.k.a Zonula occludens • Barrier • prevent passage of substance from one cell to another • Found close to apex of cells. • Proteins reqv. is occludin & cingulin	⇒ Connect one cell to another cell ⇒ Both cell acts as single unit ⇒ Intercalated disc in the cardiac muscle. ZONULA ADHERENS → Actin filament. MACULA ADHERENS → Desmosomes → connect intermed. filaments 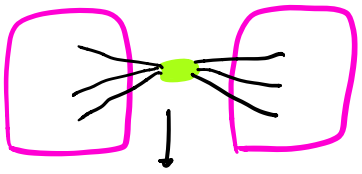 Zonula Adheren	Communicating Jn. 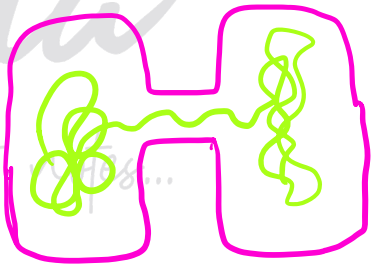 • gap = cytoplasmic communication to other cells. • Protein responsible is CONNEXIN

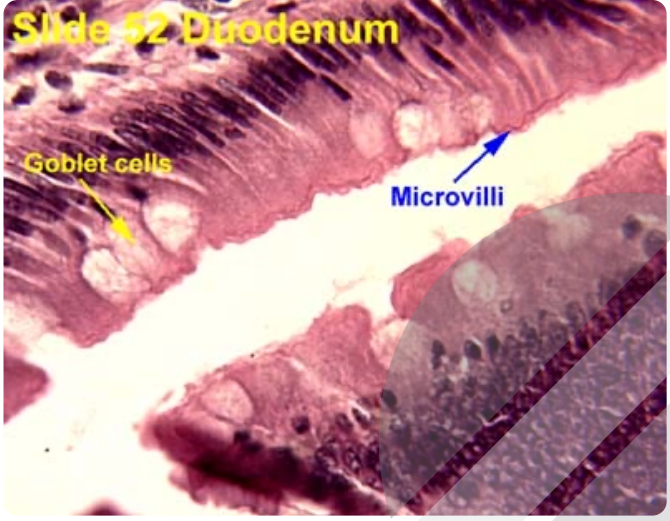

Microvilli

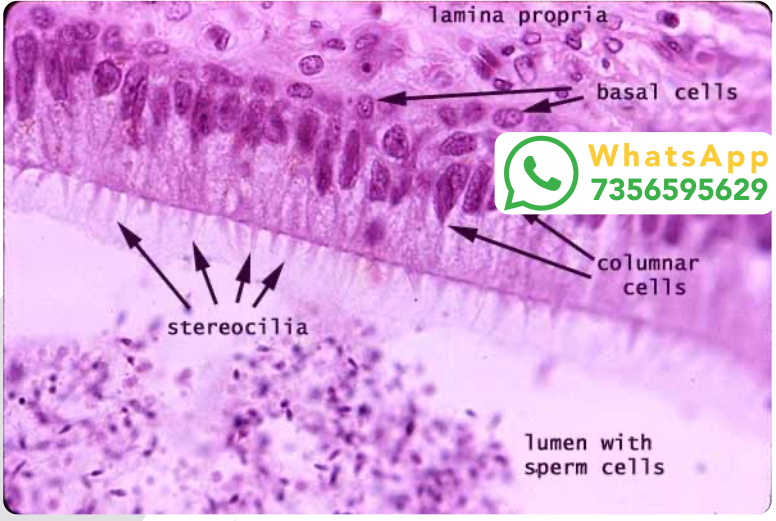

WhatsApp 7356595629

Stereocilia

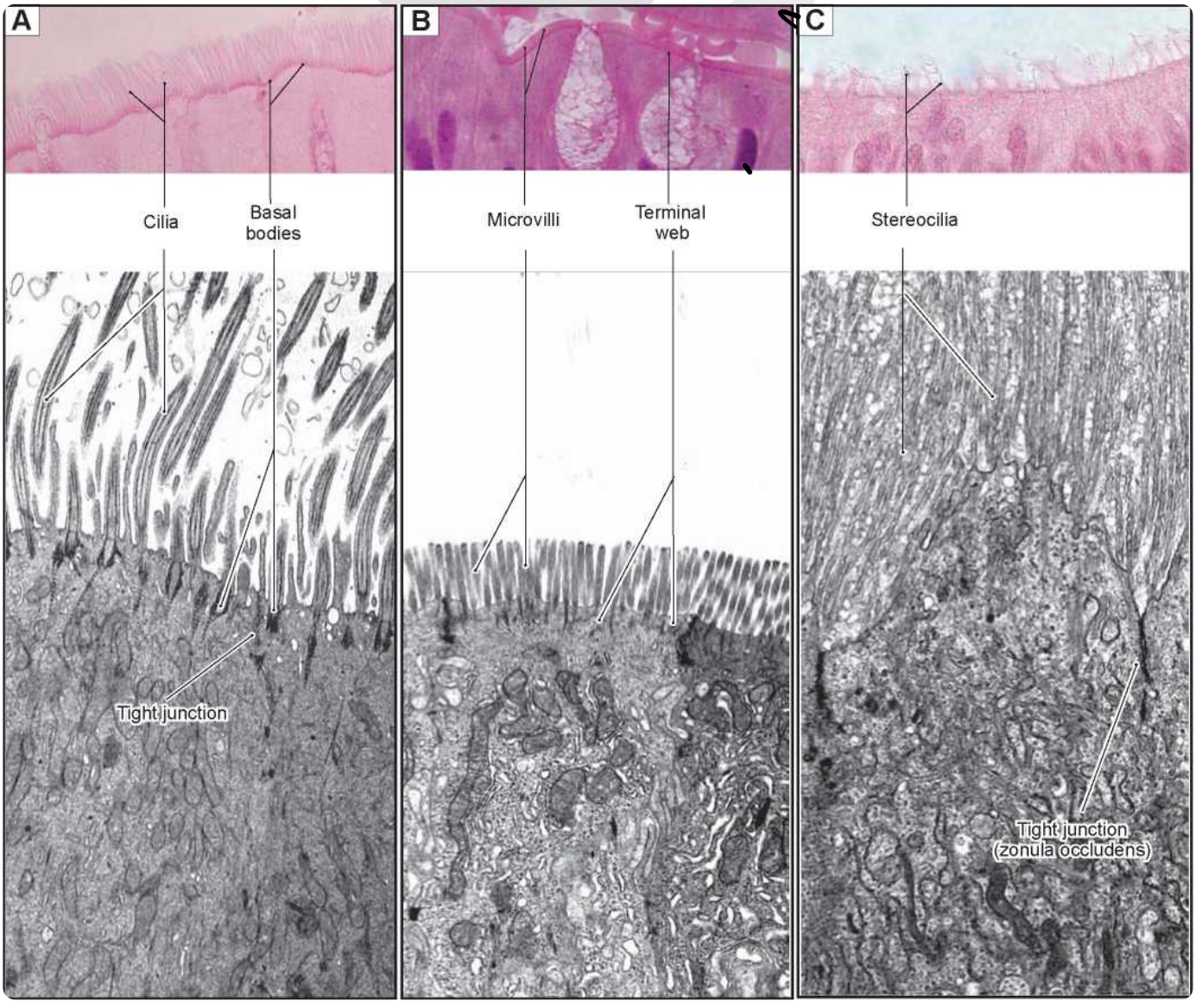

Telegram = notespaedia
WhatsApp 7356595629

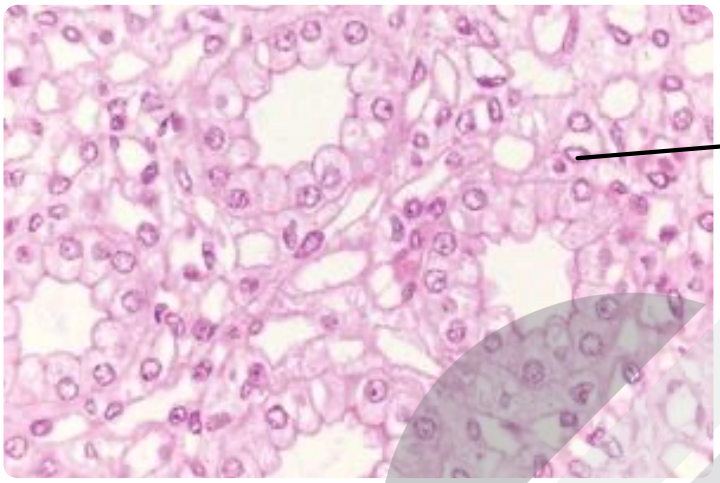

Round Nucleus

Cuboidal Epithelium

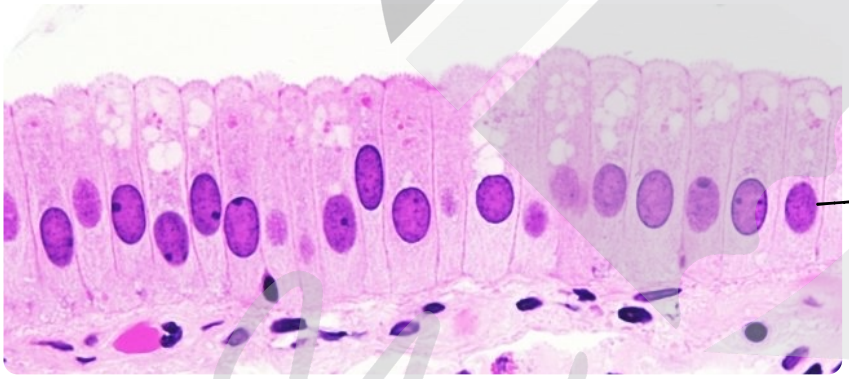

Elongated nucleus

Columnar Epithelium

squamous epithelium

} Apical layer [flat nucleus]

↑ replaced by

} Basal layer (mitotic layer)

A 46 yr old ♀ diagnosed to have hypothyroid. Her thyroid follicle lined by :-

a) Simple columnar

b) Simple cuboidal

Thyroid follicle

Germinal epithelium

Telegram = notespaedia
WhatsApp 7356595629

c) Simple squamous → Ovary
d) Stratified squamous → Tubules of kidney

HYPERTHYROID → simple columnar

HYPOTHYROID → simple squamous.

AIIMS'18 PG

Q: Epiglottis is lined by
a) Stratf. squamous
b) Simple columnar
c) Simple cuboidal
d) Psuedostratified ciliated columnar
e) Stratified cuboidal.

EPIGLOTTIS
- Lingual → Tongue ⇓ Stratf. Squamous
- Larynx → Respiratory Epithelium ⇓ Psuedostratified ciliated columnar

Q: Not correctly matched about the lining of urethra
a) Urethra opening → stratf. Squamous (T)
b) Penile urethra → Stratf. columnar. (T)
c) Membraneous Urethra → Transitional Epithelium (F) → St. columnar
d) Prostatic urethra → Transitional epithelium (T)

Notespaedia
More than just notes...

Telegram = notespaedia
WhatsApp 7356595629

Q. All the following are lined by simple squamous except

a) B.V
b) Pleura
c) Ependyma
d) Bowman's Capsule

i) Blood vessel
ii) Bowman's Capsule
iii) Body Cavity
iv) Alveoli

Q. All the following are lined by Stratf. cuboidal except.?

a) Sweat glands } ecto
b) Sebaceous glands → skin epith.
c) Salivary glands } exo
d) Pancreas

Ducts exocrines & sweat glands

AIIM/DNB
Q. Urothelium lines all except

a) Ureter
b) Calyces
c) Urinary Bladder
d) Membraneous urethra → stratif. columnar.

AIIM'19
Q. Identify the organ

a) Gall bladder
b) Urinary Bladder
c) Skin
d) Trachea

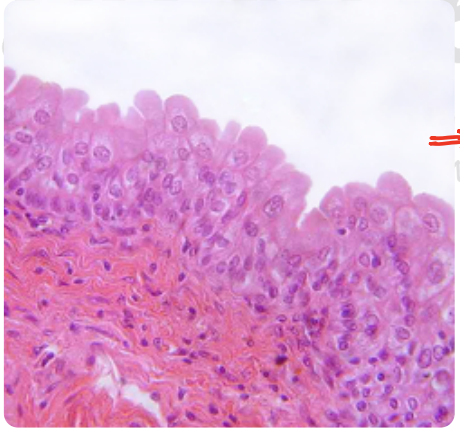

⇒ Transitional Epithelium
{Umbrella shaped cells}

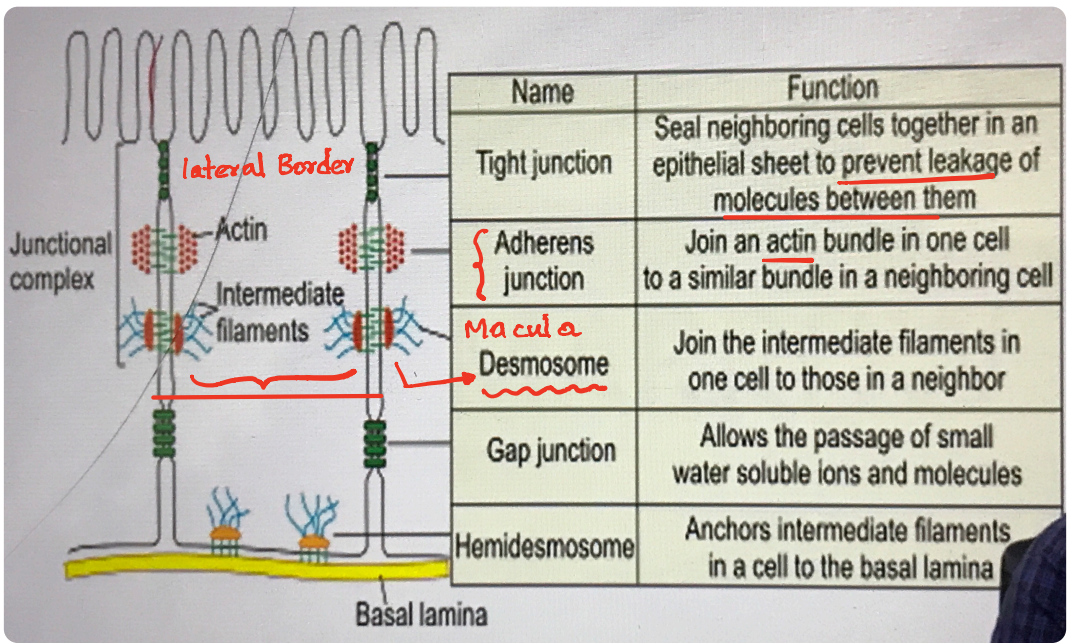

Name	Function
Tight junction	Seal neighboring cells together in an epithelial sheet to prevent leakage of molecules between them
Adherens junction	Join an actin bundle in one cell to a similar bundle in a neighboring cell
Macula Desmosome	Join the intermediate filaments in one cell to those in a neighbor
Gap junction	Allows the passage of small water soluble ions and molecules
Hemidesmosome	Anchors intermediate filaments in a cell to the basal lamina

Q. Cell junction allowing exchange of cytoplasmic molecules between two cells are called {AI 2003, DNB 2004}

Telegram = notespaedia
WhatsApp 7356595629

a) Gap junction
b) Tight Junction
c) Anchoring Junctions
d) Focal junctions

AIIMS 17
Q. Intercalated disc made up of all except ?

a) Zonula occludens
b) Zonula adherens
c) Macula adherens (desmosomes)
d) Gap junction

Glands :-

- Epithelium : Secretory function

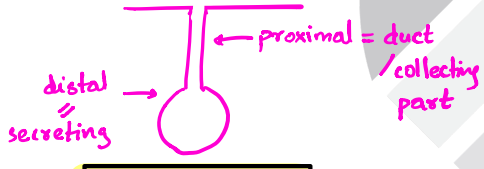

EXOCRINE GLANDS

- pour secretion to ducts
- Secretes ENZYMES

Unicellular
Q. ⇒ goblet
⇒ exocytosis
⇒ Secrete Mucin
⇒ H&E : pale app.

Multicellular
⇒ secrete into ducts

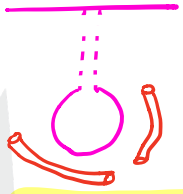

ENDOCRINE GLANDS

- pour secretion to blood vessels
- Secretes HORMONES

Based on type of secretion :-

1) Watery → Serous acini
2) Mucous → Mucous acini
3) Mixed

Notespaedia
More than just notes...

Telegram = notespaedia
WhatsApp 7356595629

Serous Acini

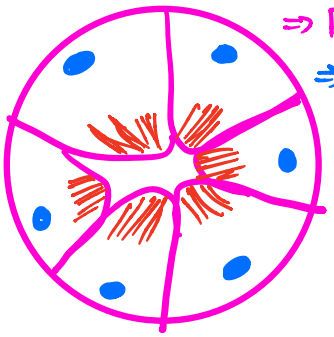

⇒ Pyramidal Cells
⇒ Round nucleus towards the base
⇒ Highly eosinophillic
⇒ Lumen is small

Mucous Acini :

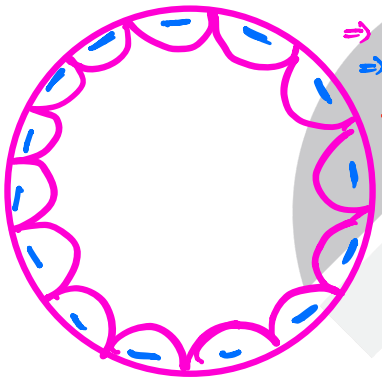

⇒ cubidal / columar
⇒ Flat nuclues = mucin push nucleus towards the base
⇒ Not eosinophillic
⇒ Lumen size more

Mixed : Both serous & mucous Acini.

- Serous gland → Majority Serous acini + few mucous acini.
  Eg:. Parotid gland
- Mucous gland → Majority mucous + few serous acini.
  Eg:. Sublingual gland.
- Mixed gland → Serous + Mucous acini

Serous demilunes → mucous acini capped with serous acini



- Eg: Submandibular gland.
- Reduce the consistency of mucouse secretion

Notespaedia
More than just notes

WARNING : THIS IS NOT THE COMPLETE VERSION OF ELITE NOTES

Telegram = notespaedia
WhatsApp 7356595629

Based on mode of secretion

MEROCRINE.	APOCRINE	HOLOCRINE
⇒ Secretions poured by Exocytosis ⇒ Intact glands 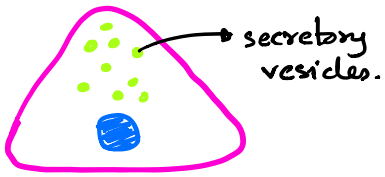 secretory vesicles. ⇒ Found in all sweat glands & exocrine glands	⇒ Apical part of gland pinched off ⇒ Apical part detatched Eg:- Atypical swt. glands over Axilla, pubis & mammary glands.	⇒ whole cell disintegrates ⇒ Basal layer · layer of cells · Basal cell is mitotic nature Eg:- Sebacious gland

Based on secretory unit:-

SIMPLE



simple tubular → Crypts of Lieber kuhn

Branched tubular → Fundic glands

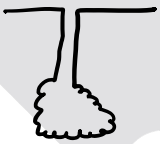

Simple coiled tubular → Sweat glands

COMPOUND / Branched.

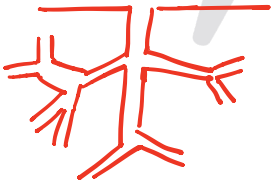

- Compound tubular → BRUNNER's gland
- Compound alveolar
- Compound alveolar

Parotid gland:-

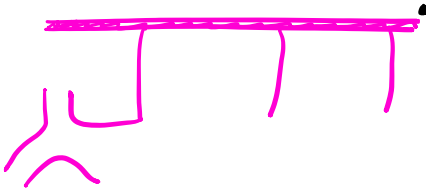

capsule: false ⇒ from investing layer of deep cervical fascia

Lobes → Lobules → Acini / Serous Acini

Inter lobular duct → LOBAR DUCT

Notespaedia
More than just notes...

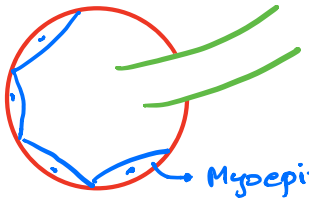

drained by

Intercalated duct. ⟶ Straight duct

WhatsApp 7356595629

Myoepithelial cell : wraps the alveoli & intercalated duct. squeeze the secretions and pour into the duct.

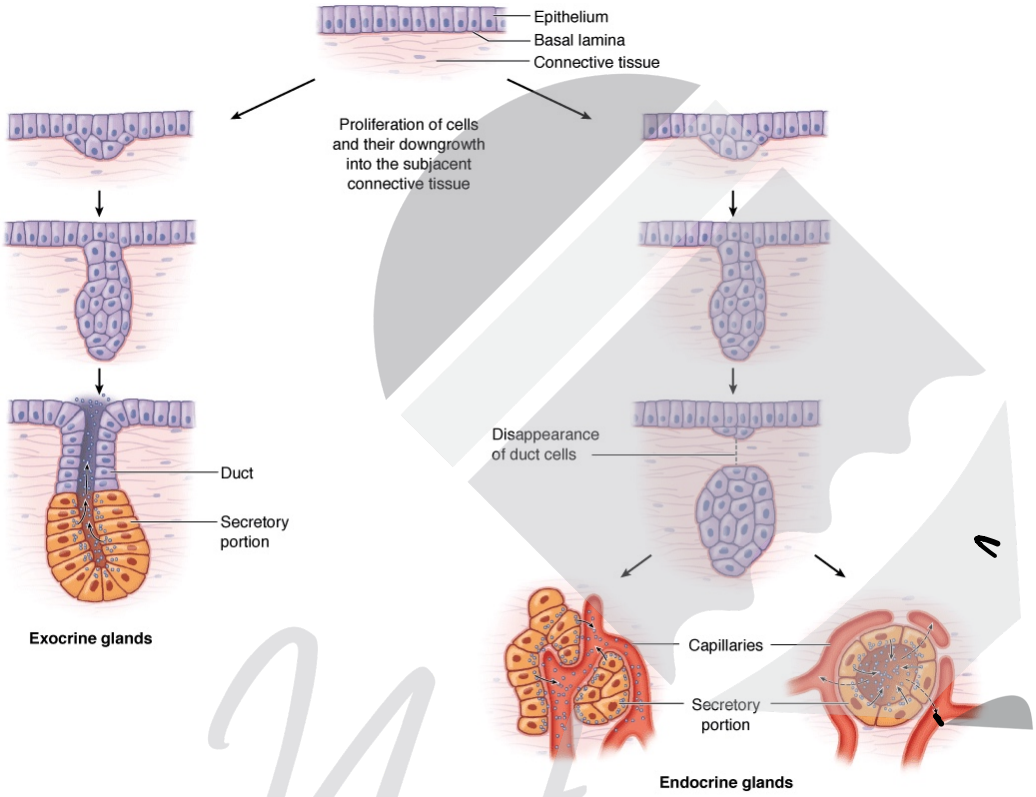

Source: Mescher AL: *Junqueira's Basic Histology: Text and Atlas, 12th Edition*: http://www.accessmedicine.com

Copyright © The McGraw-Hill Companies, Inc. All rights reserved.

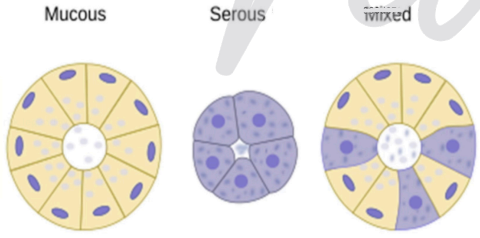

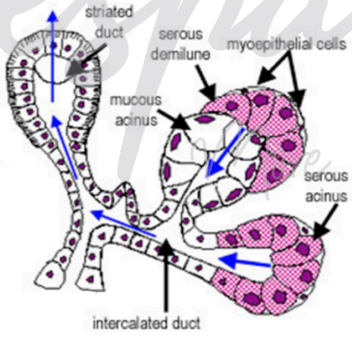

Holocrine Gland

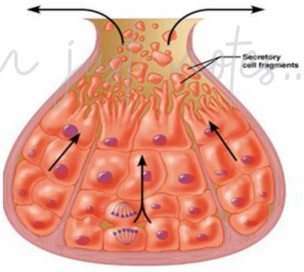

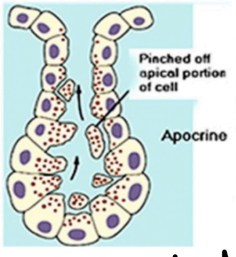

Mammary gland

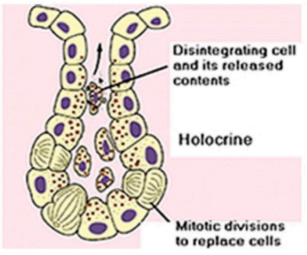

Sebaceous gland

Eccrine Gland

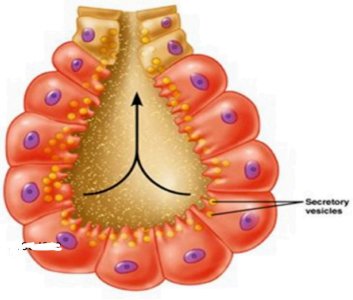

WARNING : THIS IS NOT THE COMPLETE VERSION OF ELITE NOTES

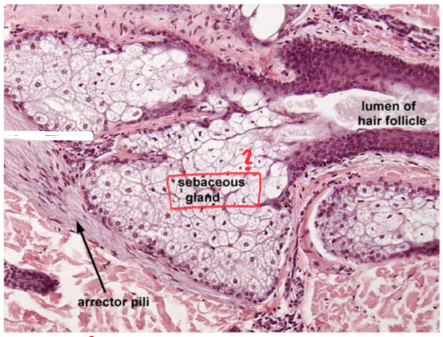

AIIMS'17 Hair Follicle

Q. Which of the following is a holocrine gland (DNB'13)
a) Sweat gland
b) Breast
c) Pancreas
d) Sebaceous Gland

Telegram = notespaedia
WhatsApp 7356595629

Connective Tissue:

- Maintain the form of body & organs
- Provide support
- Made up of cells & matrix
  - → Fibers
  - → Ground substance

Cells:

1) Named according to their fnx

eg:
- Blast → produce matrix
- cyte → maintain matrix
- clast → destroys matrix

Eg: Osteoblast, Osteocyte, Osteoclast → loctn: bone
Fibroblast, Fibrocyte, Fibroclast → produce: fibres.

Special cells

Mast cells	Macrophages
• Inflammatory Rn.	• Immune reactions
• Histamine secretion	• phagocytic

Matrix
- → Fibres
- → Ground substance

Fibres
- → Elastic
  - ⇓
  - 1) Yellowish
  - 2) Individual fiber
- → Collagen
  - ⇓
  - • white fibres
  - • found in Bundles
- → Reticular
  - ⇓
  - • Anchor to the surrounding connective tissue

Notespaedia
More than just notes...

contd.

Telegram = notespaedia

Elastic

⇓

3) Not found in bundles

4) Special stains req. to demonstrate

Collagen

⇓

- Long & wavy form

Type I	Bones, tendons Ligament, capsule
Type II	Hyalin cartilage Elastic Cartilage
Type III	Spleen, B.M, L.N
Type IV	Basement membr., Lens capsules.

Reticular

- Anchor to the surrounding connective tissue

WhatsApp 7356595629

Ground Substance :-

- Present b/w cells & fiber
- Clear colourless viscous fluid

Ground substance

Blood → Plasma

Bone → Minerals

Notespaedia
More than just notes...

Classify Connective tissue

LOOSE C.T

⇓

loosely arranged cells & fibres

Areolar	Adipose
• Beneath skin	• Beneath skin
• mast cells /macrophage	• fats
• support	• storage

DENSE C.T

Regular

Collagen fibres arranged in Bundles regularly

Eg:- i) Ligament
ii) Tendons
iii) Aponeurosis

Irregular

AIIMS'17

1) Periosteum
2) Capsule

WhatsApp
7356595629
Telegram = notespaedia

Special Connective Tissue :-

- Bones
- Cartilage
- Muscle.

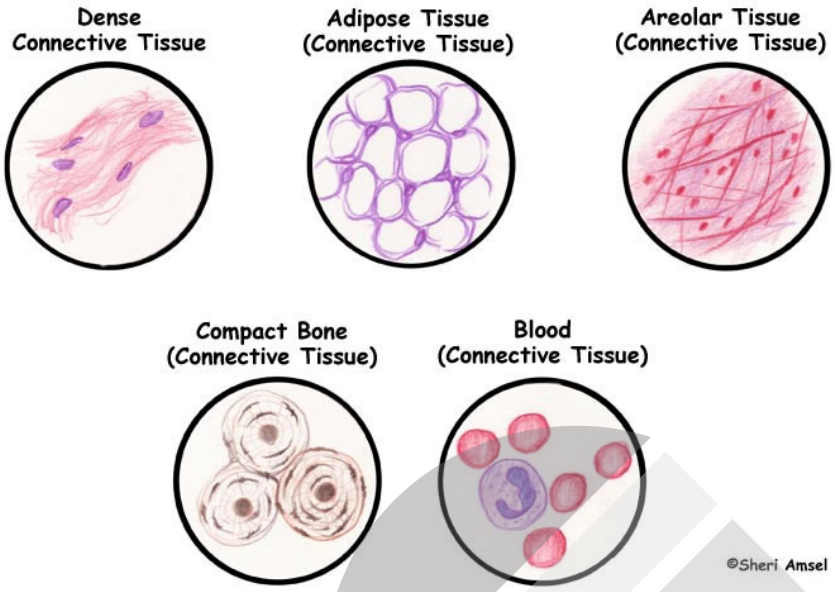

Cartilage :-

Special Connective tissue :-

Based on fibers & ground substance

- Hyaline
- Elastic
- Fibrous

Hyaline Cartilage :-

- Glossy / shiny
- cells → matrix
  - fibers
  - ground substance
- cells in the hyaline cartilage
  → Chondrocytes
  → placed in → Lacuna

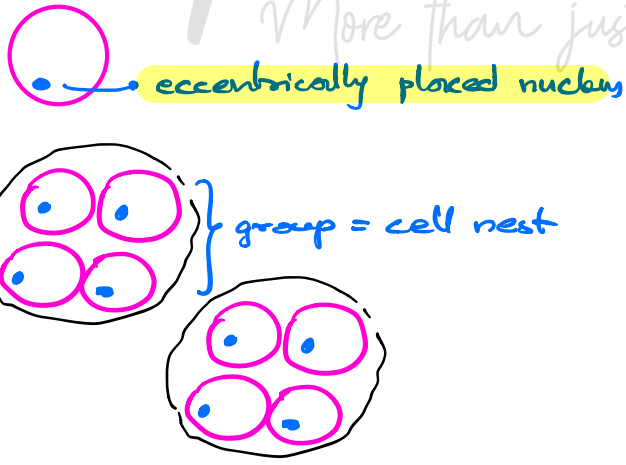

Notespaedia
More than just notes...

- Type II collagen fiber.
- matrix is glossy in appearance
- Refractive Index of type II collagen is same as that of ground substance.
- Ground substance in Hyaline made up of proteoglycan and chondroitin sulfates.

WhatsApp 7356595629

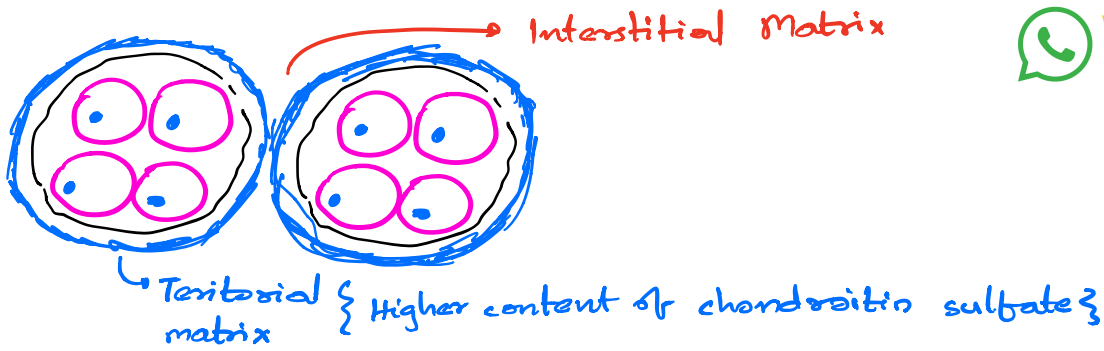

Covering: Perichondrium

- Outer layer (FIBROUS) → contain → FIBROBLAST
- Inner layer (CHONDROGENIC LAYER) → contain → chondroblast

Location/ Eg. of Hyalin Cartilage:

1) Articular Cartilage
2) Costal Cartilage
3) Epiphyseal Cartilage
4) Embryonic Cartilage
5) Respiratory Cartilage

Elastic Cartilage:

1) Cells → Chondrocytes

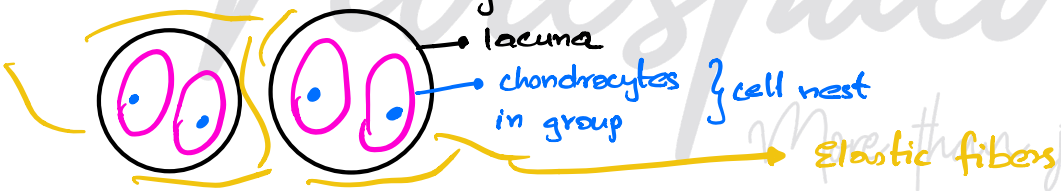

2) Type II collagen fiber + Elastic fibers
   - Elastic fibers → special stain req. for demonstration
3) Perichondrium +.

Eg. of Elastic Cartilage:

E → Eustachian tube
E → Ear lobe
E → Epiglottis

Notespaedia More than just notes...

C → Corniculate
C → Cuneiform & Apex of arytenoids

WhatsApp 7356595629
Telegram = notespaedia

Fibro Cartilage:

- Chondrocytes → arranged in rows

Q AIIMS'12

- Type I Collagen fibres
- Perichondrium is absent in white fibrous cartilage

HYALINE	ELASTIC	FIBROUS
1. Nest	1. Nest	1. Rows
2. Type II collagen	2. Type II Collagen	2. Type I collagen
3. Perichondreum (+)	3. Perichondrium (+)	3. Perichondrium (−)
4. • Articular cartilage • Costal cartilage • Embryonic cartilage • Epiphyseal • Resp. cartilage	4. • Ear lobe • Epiglottis • E.T • Corniculate • Cuneiform	4. • Meniscus • Articular disc • Glenoid labrum • Intervertebral disc

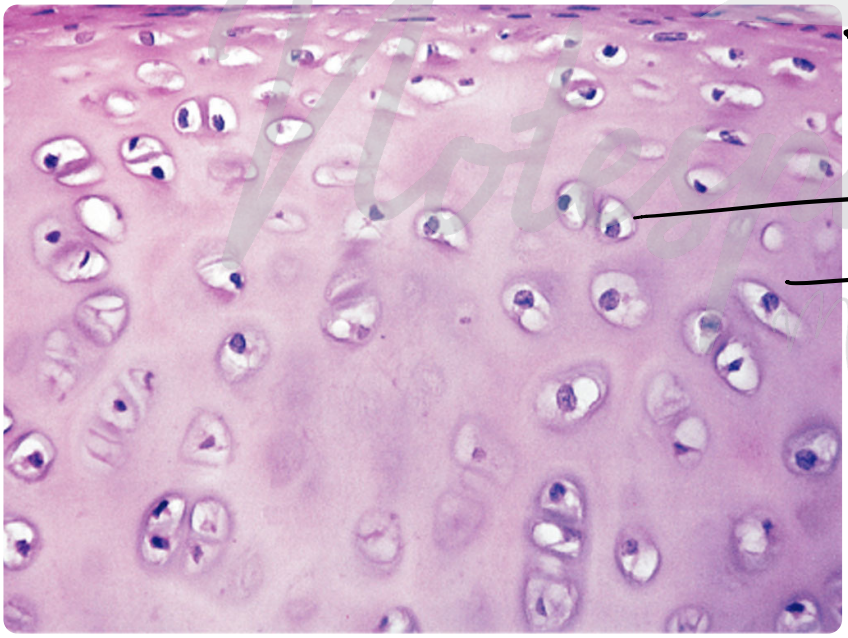

HYALINE CARTILAGE

Notespaedia
More than just notes...

Telegram = notespaedia
WhatsApp
7356595629

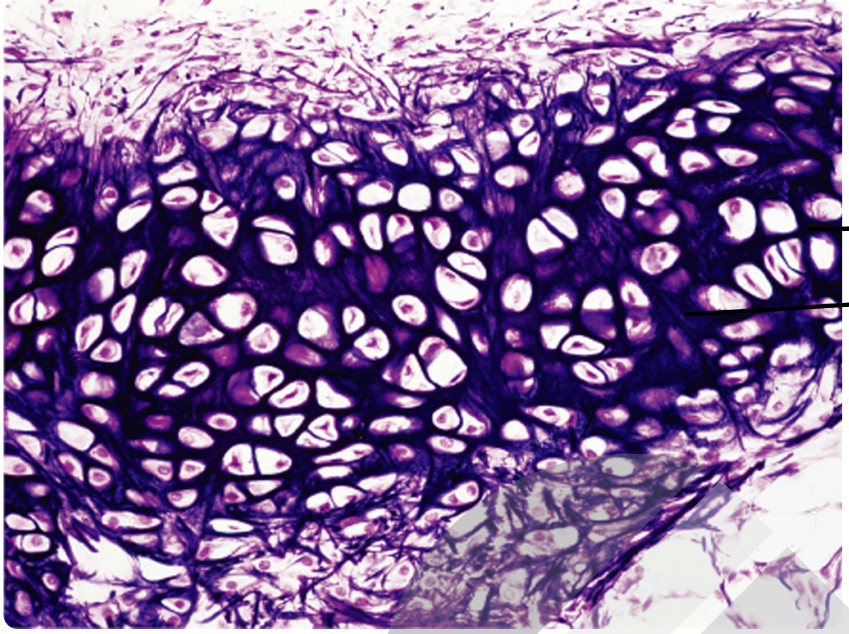

ELASTIC CARTILAGE

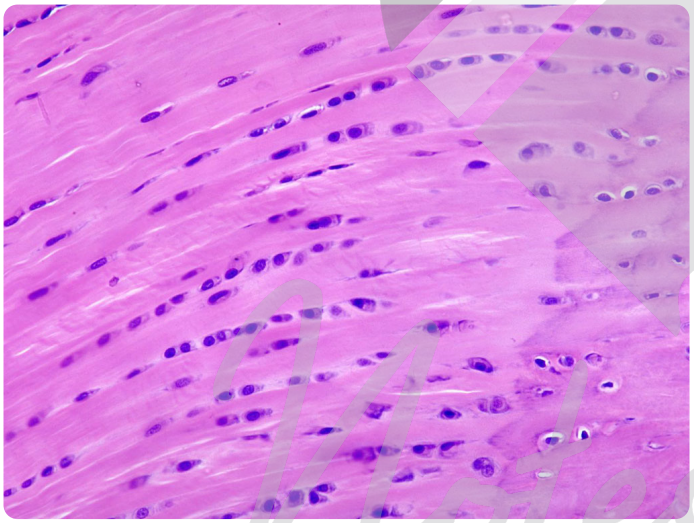

Fibrous Cartilage

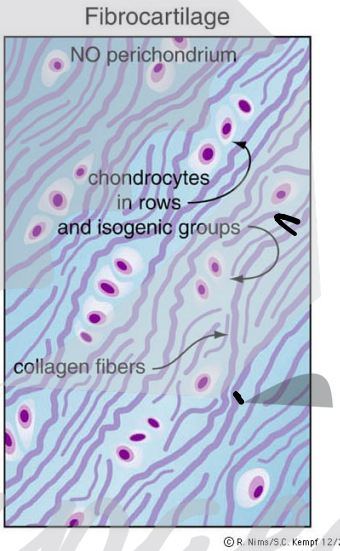

AIIMS16

Q. An Image of haematoxylin and Eosin stained section of a tissue is shown below. The tissue shown in Lower two thirds of this picture is found in?

a) Articular Disc → white fibrous
b) Intervertebral Disc
c) Epiphyseal plates ✓
d) Pinna of ear → elastic cartil.

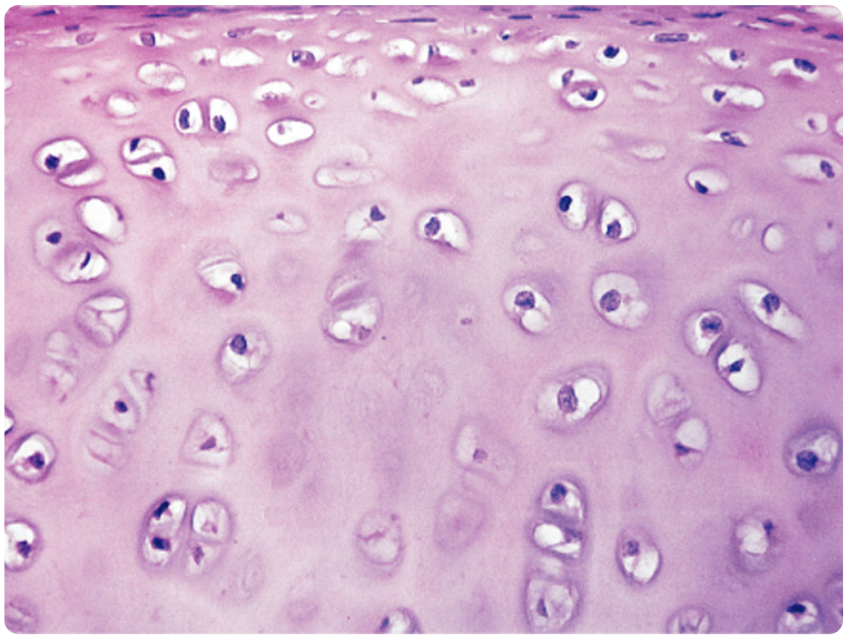

Notespaedia
More than just notes

Q. wrong pair about type of collagen

a) Hyaline → Type II

b) Lens capsule → Type I

c) Blood vessel → Type III

d) Spleen → Type III

AIIM'15

Q. Reticular fibres of collagen are p/i all except → Type III

a) Thymus → Collagen fibre Type I

b) B.M

c) Spleen

d) L.N

Telegram = notespaedia
WhatsApp 7356595629

BONES :-

- Special Connective tissue.
- Cells present → i) Osteoblast
  ii) Osteocytes
  iii) Osteoclast.
- Fibres : Collagen fibres
- Matrix : Ca, PO_4, minerals.

Parts of long bone

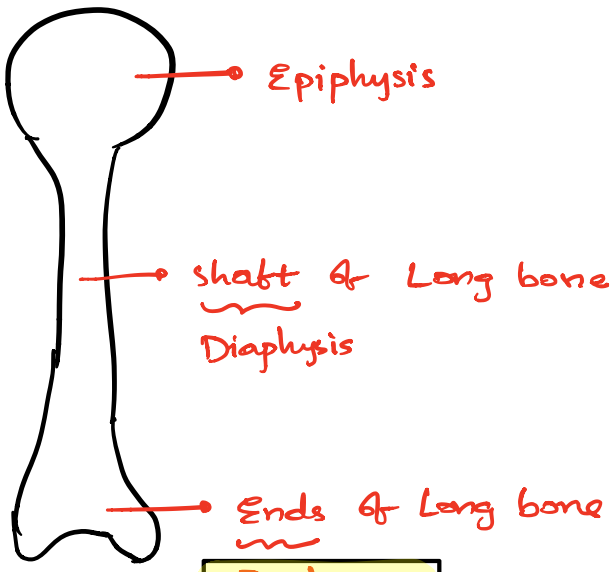

Epiphysis

- **Traction type**
  - d/t pull of muscles
- **Pressure Type**
- **Atavostic type**
  - fused to neighboring

- Eg:- Greater trochanter
  Greater tuberosity
  lesser trochanter

. Takes part in joint formation.

Eg:- Head of Humerus
Head of femur

bone for fnx. reason

Telegram = notespaedia

Eg:- Coracoid process

contd.

Abberent → Not usually present

eg:- Head of 1st metacarpel bone.
Base of other metacarpel bone

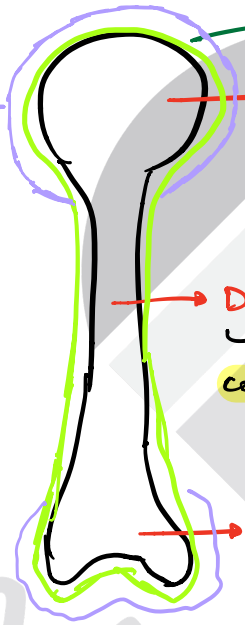

Compact bone

Structural Unit : Osteon.

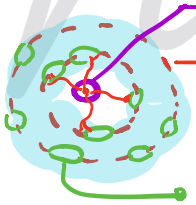

Spongy Bone :-

- Faces marrow / medullary cavity
- No osteon
- No central canal
- Spicules → Trabecular → • Osteocyte
  • matrix
  • canaliculi

Notespaedia
More than just notes...

WhatsApp 7356595629
Telegram = notespaedia

- Blood vessels present in periosteum → central canal → marrow cavity → Trabeculae opening

Central Canal

HAVERSIAN CANAL
↓
lie in direction of Osteon

Perforating Canal:

VOLKS MAN CANAL
↓
lies ⊥r to osteon

MARROW CAVITY:

Red B.M
↓
- Haematopoesis
- Flat bone = sternum
  Ribs
  scapula.

White B.M
↓
- Fat storing area
- storage

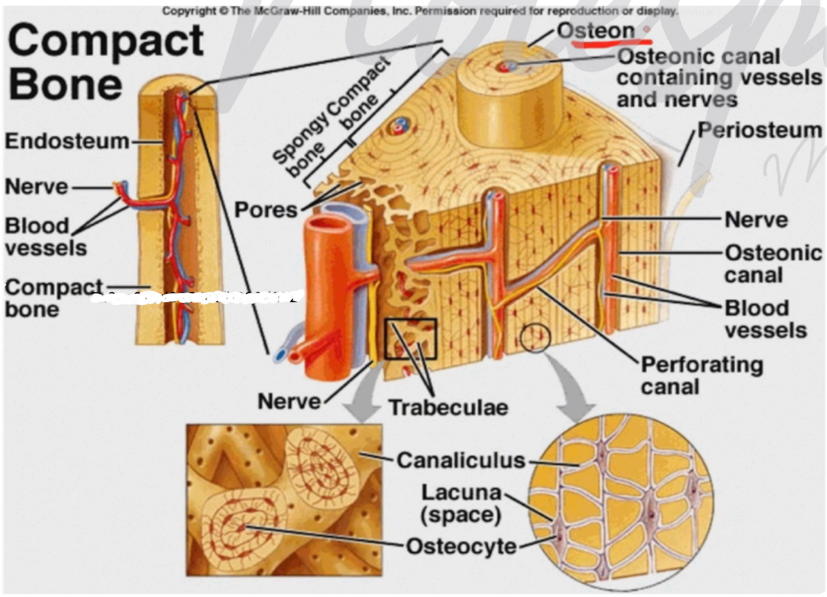

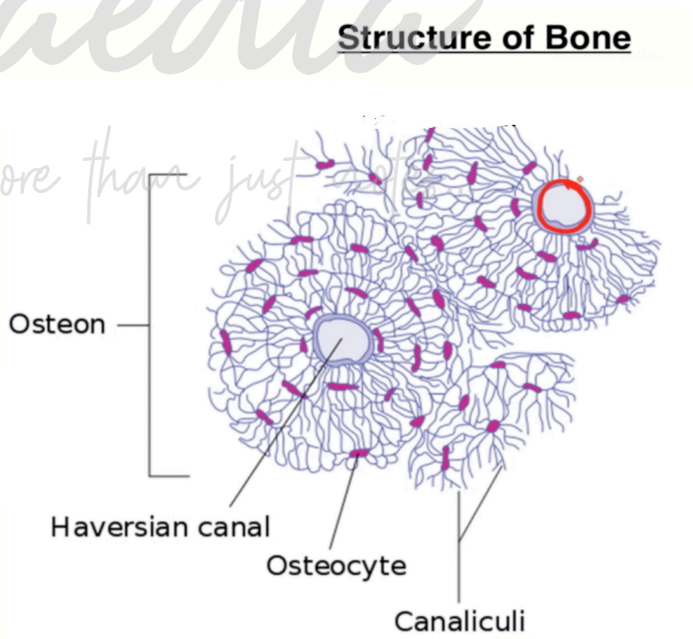

Q. Which of the following is not epiphysis?
a) Greater trochanter → Traction
b) Lesser tuberele → Traction
c) Deltoid tuberosity
d) Corocoid Process. → Atavastic

WhatsApp 7356595629
Telegram = notespaedia

2. Properly matched about the epiphysis

a) Traction type : coracoid process
b) Aberrant : head of first metacarpal bone
c) Pressure : lesser tubercle
d) Atavastic : head of radius.

Muscle :-

SKELETAL

- Voluntary
- Fibres are parallel to each other

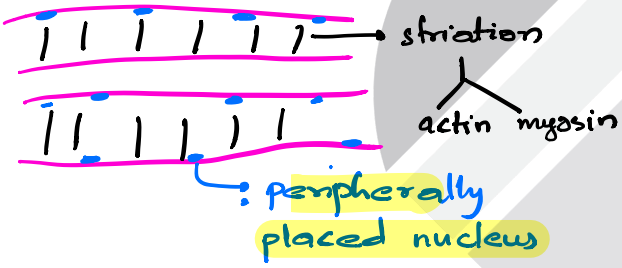

- Multinucleated

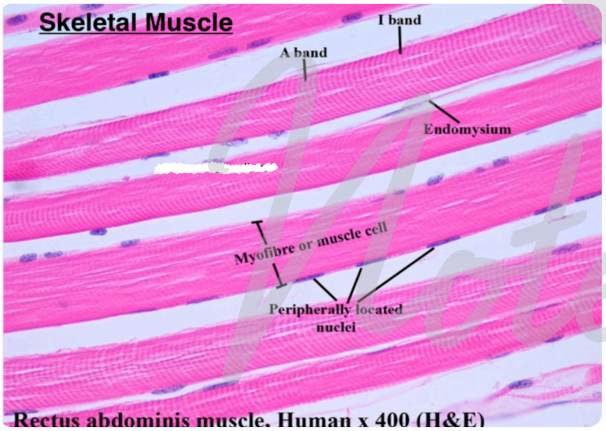

CARDIAC

- Involuntary
- Heart muscle
- Fibres are parallel to each other

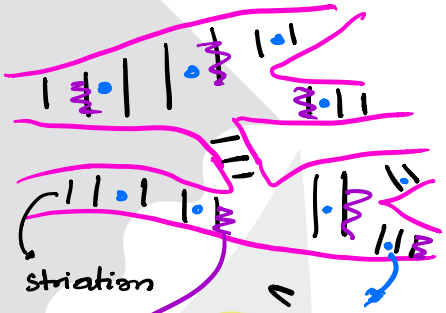

Intercalated disc ⇓ connect all protein fibres and act as single unit.

Cardiac Muscle

Cardiac muscle image under special microscope

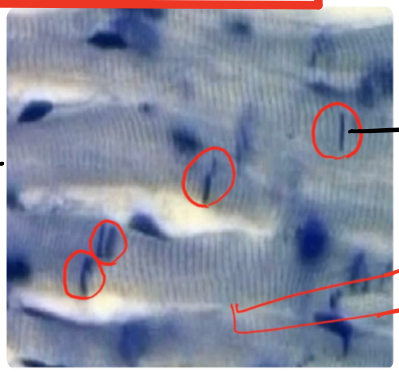

Q. Heart muscle true are all except (AI 2007)

a) Acts as syncytium

b) Has multiple nuclei ✗ } single nuclei

c) Has gap junctions

d) Has branching

Telegram = notespaedia
WhatsApp
7356595629

EXTRA POINTS FROM MARROW QBANK / MARROW PEARLS

- Protoplasm → includes cytoplasm + nucleus.

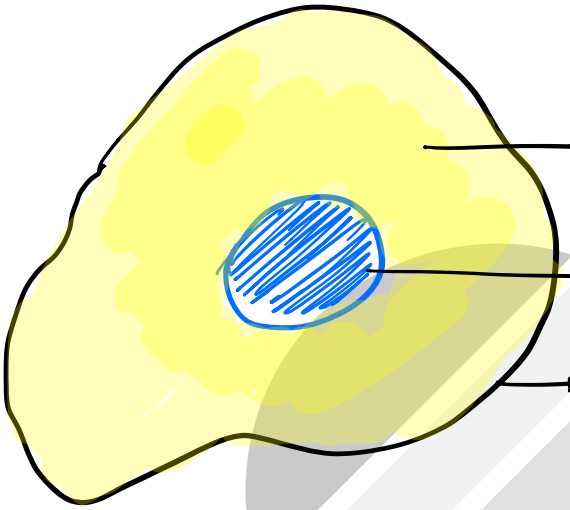

CYTOPLASM (gel around nucleus) } PROTOPLASM (all living matter in cell)

NUCLEUS

CELL / PLASMA MEMBRANE

AIIM'17 Q. The structure marked in the e micrograph with asterisk is

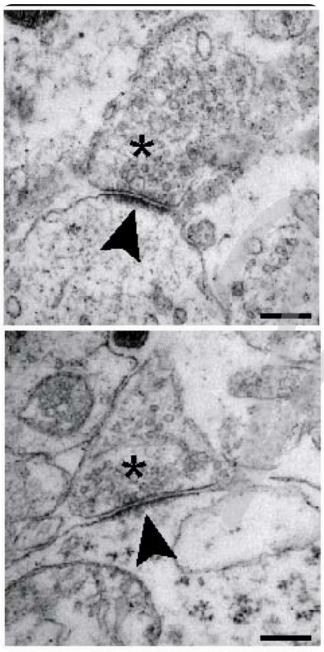

a) Mitochondria
b) Golgi bodies
c) Secretory Vesicles → involved in electro chemical signaling in the brain and neuromuscular junctions.
d) Ribosomes

Mitochondria → appears round / elliptical bodies

Golgi Bodies → cisternal / tubular

Ribosomes → chain of granular structures K/a polyribosomes

Q.

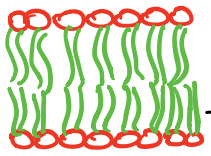

Cell membrane → predominantly consist of Protein taking mass ratio

→ Hydrophobic lipid bilayer

→ Hydrophillic head

Q. 1) Pinocytosis → process of absorption of fluid / small molecules into cells

2) Endocytosis → process of large molecules enter in to cells by invagination & formation of vescicles

Telegram = notespaedia
WhatsApp 7356595629

3) Phagocytosis → Endocytosis of foreign material (bacteria)

4) Exocytosis / Reverse pinocytosis → Process of releasing molecules that are produced within the cytoplasm to the exterior.

Q. VACUOPLASM → cytoplasm within the channel of ER
CYTOSOL / HYALOPLASM → cytoplasm outside the channel of ER

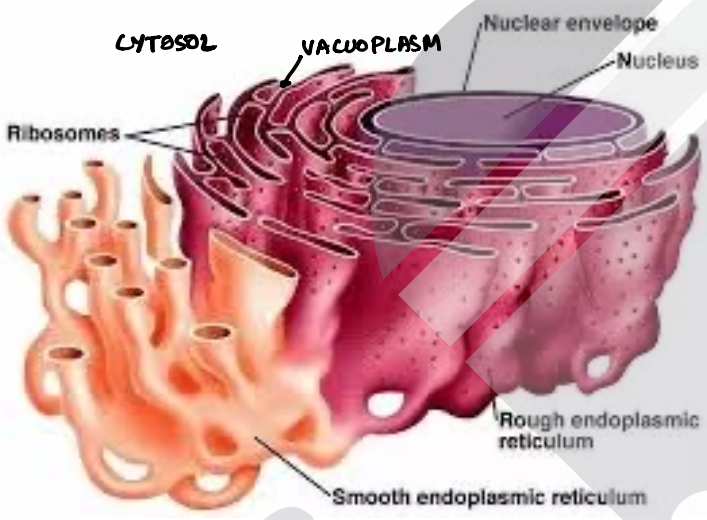

Notespaedia
More than just notes...

WARNING : THIS IS NOT THE COMPLETE VERSION OF ELITE NOTES